

## Adult urticaria pigmentosa: successful treatment in association with phototherapy

### *Urticária pigmentosa no adulto: tratamento bem-sucedido em associação com fototerapia\**

Rafael Capelo Costa<sup>1</sup>, Juliana D'Andrea Molina<sup>2</sup>, Marilda Aparecida Milanez Morgado de Abreu<sup>3</sup>

Costa RC, Molina JD, Morgado de Abreu MAM. Adult urticaria pigmentosa: successful treatment in association with phototherapy / *Urticária pigmentosa no adulto: tratamento bem-sucedido em associação com fototerapia*. Rev Med (São Paulo). 2020 July-Aug;99(4):400-4.

**RESUMO:** *Introdução:* A urticária pigmentosa em adultos é uma forma de mastocitose rara e persistente, frequentemente com manifestações sistêmicas e acometimento da medula óssea, e manifestações cutâneas menos evidentes, ao contrário do que ocorre na infância. *Objetivo:* Relatar um caso de início na fase adulta, com lesões cutâneas leves, que evoluiu com sintomas de liberação histamínica, porém sem acometimento sistêmico. *Metodologia:* As informações foram obtidas através de revisão do prontuário, entrevista com o doente, registro fotográfico e revisão da literatura. *Conclusão:* O diagnóstico correto e a investigação precoce do acometimento de outros órgãos são importantes, bem como o tratamento adequado e prevenção de reações anafilactoides. A fototerapia é opção interessante de tratamento nos casos refratários.

**Descritores:** Urticária pigmentosa; Mastocitose cutânea; Mastocitose sistêmica.

**ABSTRACT:** *Introduction:* Adult urticaria pigmentosa is a rare and persistent form of mastocytosis, often with systemic manifestations and involvement of the bone marrow, and less evident cutaneous manifestations, contrary to what occurs in childhood. *Objective:* The authors aim to report a case of adult onset, with mild skin lesions, and development of symptoms of histamine release, without systemic involvement. *Methodology:* The information was obtained through review of the medical record, interview with the patient, photographic record, and a literature review. *Conclusion:* The correct diagnosis and the early assessment of involvement of other organs is important, as well as adequate treatment and prevention of anaphylactoid reactions. Phototherapy is an interesting treatment option for refractory cases.

**Keywords:** Urticaria pigmentosa; Mastocytosis, cutaneous; Mastocytosis, systemic.

\*Trabalho realizado no Hospital Regional de Presidente Prudente, SP, Universidade do Oeste Paulista.

1. Médico dermatologista pela SBD, clínica privada. ORCID: <https://orcid.org/0000-0002-3224-3336>. Email: [capelo@gmail.com](mailto:capelo@gmail.com).  
2. Médica dermatologista pela SBD, clínica privada. ORCID: <https://orcid.org/0000-0001-9261-5739>. Email: [julianadandrea@gmail.com](mailto:julianadandrea@gmail.com).  
3. Médica dermatologista pela SBD, mestrado e doutorado em ciências. Serviço de Dermatologia do Hospital Regional de Presidente Prudente/Universidade do Oeste Paulista. ORCID: <https://orcid.org/0000-0001-9099-6013>. Email: [marilda@morgadoeabreu.com.br](mailto:marilda@morgadoeabreu.com.br).

**Endereço para correspondência:** Rafael Capelo Costa, Avenida Santos Dumont 2727 sala 301. Fortaleza, CE. CEP: 60150-161

## INTRODUCTION

Mastocytosis is a rare disease, with a prevalence of 2 cases per 300,000 patients attending dermatological consultation. It is characterized by the proliferation and accumulation of mast cells in the skin and/or other organs and tissues, especially the bone marrow and the gastrointestinal tract<sup>1</sup>. It is subdivided into cutaneous mastocytosis (CM), which is more frequent in children, and systemic mastocytosis (SM), which has a later onset and is usually diagnosed after the third decade of life. The latter is characterized by the accumulation of mast cells in other organs and tissues, and it can be progressive and fatal if associated with malignancy<sup>2</sup>. The cutaneous form is rare in adults, so reports about its development in middle-aged patients are scarce.

Clinical symptoms are a result of the pro-inflammatory mediators' release by activated mast cells, combined with infiltration of these cells in different organs<sup>1</sup>.

The prognosis depends on several factors, but in adults the skin lesions usually persist, and regression only occurs in the minority of cases. Most patients have a stable disease course and a normal life expectancy, as the evolution to aggressive forms is considered an exceptional event<sup>3</sup>.

We present a rare case of mastocytosis in an adult, with symptoms and lesions limited to the skin. The absence of a systemic involvement was confirmed by thorough clinical and laboratory investigation.

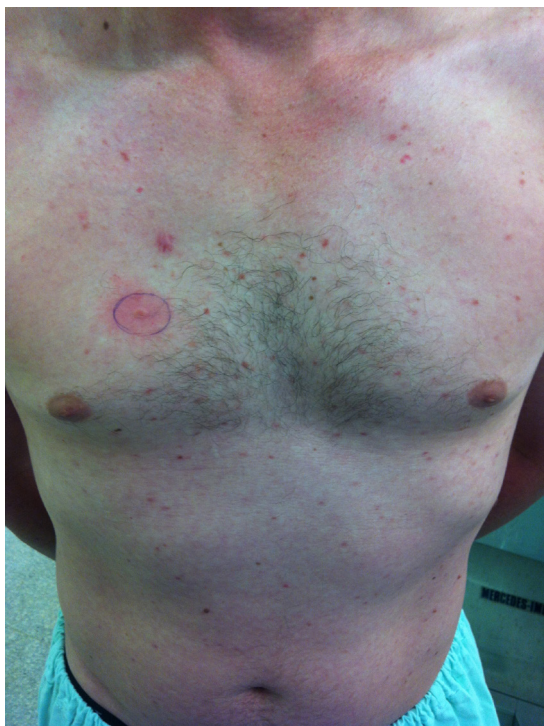

Figure 1: Erythematous papules with positive Darier's sign.

## CASE REPORT

A 36-year-old white male patient complained of skin lesions for a year. Lesions started on his forearms and progressed to the trunk in four months.

Examination showed small erythematous, edematous papules that disappeared on finger pressure on the anterior surface of the forearms and on the trunk, with a positive Darier's sign (Figures 1 and 2). Older lesions were brownish and did not blanch when pressed (Figure 3). The patient complained of itching and burning sensation. In subsequent consultations, he reported abdominal colic, dizziness, and tachycardia.

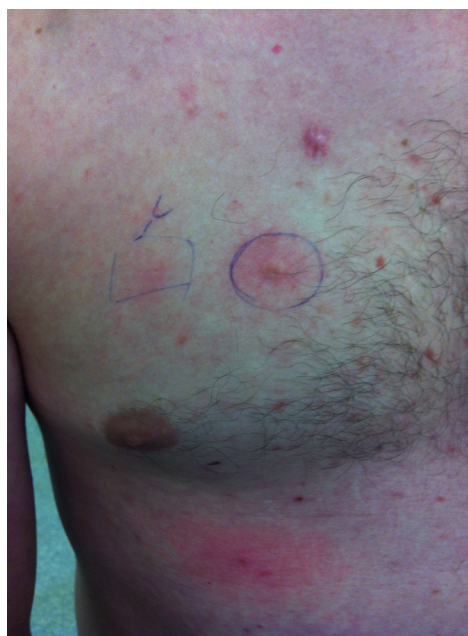

Figure 2: Detail of the Darier's sign.

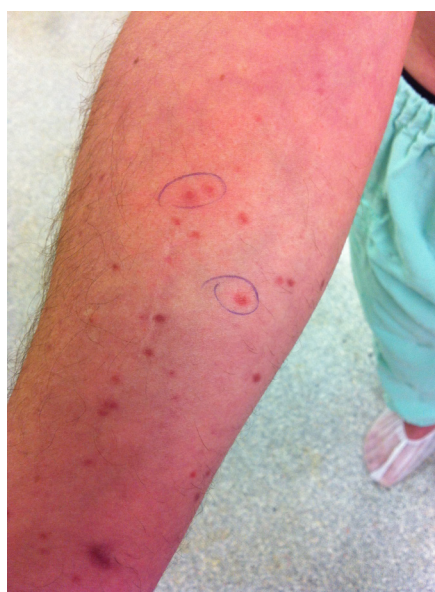

Figure 3: Older brownish papules

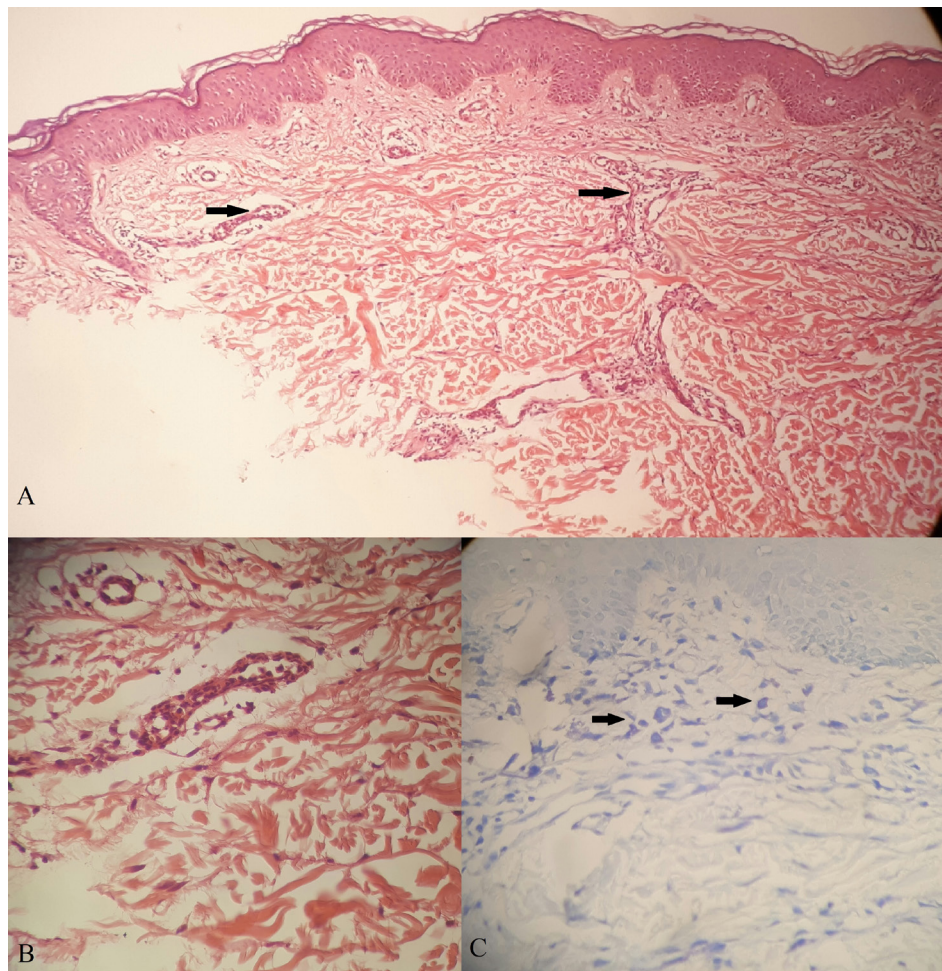
The patient did not report any previous illness and had no family history of skin conditions.

Laboratory results did not show any alteration, including serum tryptase (Table 1). The histopathology of the lesion showed residual superficial perivascular

dermatitis and 9 mast cells in a high magnification field (Figure 4). The patient was referred to cardiology, gastroenterology, and hematology. Imaging tests, bone marrow aspiration and an electrocardiogram were performed and none of them revealed any alterations.

**Table 1:** Most relevant tests

Exam	Result
LDH	522 U/L (VR =313-618)
Tryptase	13.1mcg/L (less than 13.5)
Myelogram	Rare abnormal mast cells
Immunophenotyping of peripheral blood	Did not reveal atypical cell population
Bone marrow biopsy	No increase in marrow mast cells
Radiographs: lumbosacral spine, thoracic, cervical, pelvis, skull, thorax	No significant alterations
Abdominal ultrasound	Liver steatosis, nephrolithiasis, simple renal cyst



**Figure 4:** Microscopy of the skin. A – Dermis with perivascular inflammatory infiltrate (arrows) (Hematoxylin-eosin, 100x magnification). B – Detail of the perivascular lymphocytic infiltrate (Hematoxylin-eosin, 400x magnification). C – Presence of 9 mast cells in the superficial dermis (arrows) (Toluidine Blue, 400x magnification)



Treatment with antihistamines, mast cell stabilizers and antileukotrienes was started. During disease evolution,

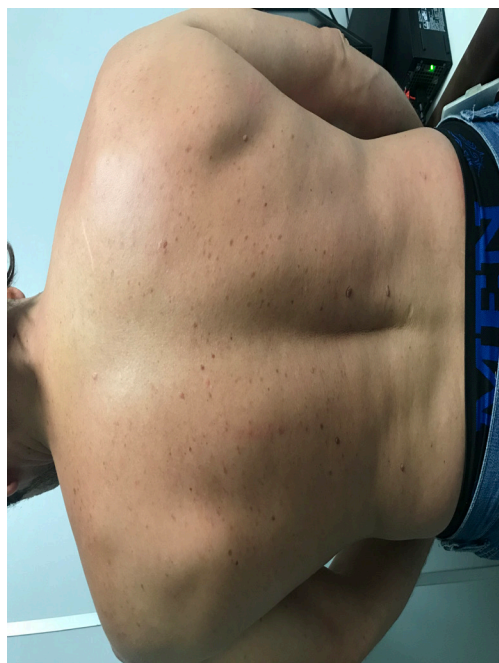symptoms and skin lesions were difficult to control, despite the drug combination (Table 2).

**Table 2:** Systemic therapy used, in chronological order of medications and respective dose, frequency and time of use

Medication (chronological order)	Dose	Frequency	Time of use
Loratadine	10mg	2x/d	6 months
Ketotifen +loratadine	1mg + 10mg	2x/d	8 months
Montelukast + ketotifen + ebastine	10mg+ 1mg + 10mg	1x/d + 2x/d +2x/d	5 months
Dexchlorpheniramine + fexofenadine*	2mg + 180mg	3x/d + 1x/d	8 months*

\*-Associated with phototherapy after this period.

NB-UVB phototherapy (narrow band ultraviolet B - range between 311-312nm) was used as combined therapy and showed satisfactory results after the sixth session, as the erythematous edematous papules and pruritus disappeared (Figure 5). Prolumina cabin – 21 NB-UVB lamps was used. Initial dose of 50mj/cm<sup>2</sup> (33”), with an increase of 50mj per session, according to adverse effects, on Tuesdays and Fridays. Maximum dose reached was 1050mj (11’40”). Remission of systemic symptoms was achieved as the skin lesions improved. Patient was discharged after 55 sessions, with an accumulated dose of 33 J/cm. Dexchlorpheniramine and fexofenadine were maintained during the sessions and after discharge. After one month, the condition recurred, and the patient had to restart the treatment.



**Figure 5:** Good response to combined NB-UVB phototherapy

## DISCUSSION

Cutaneous mastocytosis is defined by the typical exanthema, which is the major criterion, and one or two

of the minor criteria: monomorphic infiltrate with large aggregates of tryptase-positive mast cells, or more than 20 mast cells per microscopic field; or detection of a KIT mutation at codon 816 in lesional skin. Subsequently, an algorithm can be used to differentiate CM from SM, including indolent and leukemic forms<sup>4</sup>.

Pediatric patients usually suffer from CM whereas adults usually have SM. Therefore, bone marrow examination is indicated in the latter, even if serum tryptase is normal<sup>4</sup>.

CM is subdivided into urticaria pigmentosa, diffuse cutaneous mastocytosis and solitary cutaneous mastocytoma. There is also a subtype called telangiectasia macularis eruptiva perstans. Urticaria pigmentosa is the most common form and it is characterized by red-brown macules or papules with 3 to 4mm that appear on the trunk and thighs and spread symmetrically. Darier's sign (wheal reaction when the lesion is stroked) is present<sup>2</sup>.

Paroxysms are due to mast cell degranulation: body flushing, pruritic erythema, headache, palpitations, hypotension, syncope, dyspnea, left chest pain, diarrhea, paresthesia, pruritus, urticaria, bronchospasm, and blisters<sup>1</sup>.

Factors that suggest SM: blood count with anemia, leukocytosis and eosinophilia, increased levels of urinary histamine and serum tryptase > 20 ng/ml, hepatosplenomegaly or lymph node enlargement, osteoporosis, and mast cell infiltrates in the bone marrow<sup>1</sup>.

The treatment is aimed at relieving symptoms such as pruritus (use of H1-antagonists) and gastrointestinal manifestations (H2 antagonists) and avoiding triggers of mast cell degranulation, namely: friction, sudden temperature changes, intense physical exercise, stress, general anesthesia, alcoholic beverages, non-steroidal anti-inflammatory drugs, narcotics, radiological contrast and ionizing radiation. It is important that patients carry epinephrine, corticosteroids and antihistamines due to the risk of anaphylaxis. In this context, drugs such as sodium cromoglycate and ketotifen stabilize the mast cell membrane. Topical corticosteroids or excision are recommended for mast cell tumors. Cyto-reductive therapy can be used for SM. Currently, the immunobiologicals omalizumab and imatinib are being studied in severe cases

with anaphylaxis and systemic disease<sup>4,5</sup>.

Phototherapy has been used in dermatology since the turn of the 19th century. It was initially used for the treatment of psoriasis. Today, it is used in several skin diseases, especially those associated with pruritus. UVB acts in the epidermis and 10% of the dose reaches the dermal junction, while PUVA penetrates the dermis, with 30% of the dose acting in this layer<sup>6</sup>.

Phototherapy is a second-line treatment for resistant skin lesions, whether in CM or indolent SM. Little is known about the changes induced by UV in skin mast cells. UV light inhibits the release of histamine by activated mast cells and induces apoptosis. Both PUVA and NB-UVB have shown satisfactory results in studies. Brazzelli et al.<sup>7</sup> achieved complete remission of pruritus in 35% of the patients and a substantial improvement of cutaneous symptoms in all patients treated with PUVA or NB-UVB. PUVA therapy led to more rapid results and better control of cutaneous symptoms. NB-UVB therapy required lower

UV exposure to achieve good results and had a better tolerability profile<sup>7</sup>.

Due to the late onset of the condition in comparison to the epidemiological context of urticaria pigmentosa, a thorough investigation of the involvement of other organs was carried out. The systemic symptoms presented by the patient were related to the release of histamine, since they regressed with the control of skin lesions.

## CONCLUSION

The report highlights the importance of differentiating CM and SM to rule out more aggressive conditions, provide proper follow-up and improve symptoms. The association of drug therapy and phototherapy, whether NB-UVB or PUVA, should be considered in cases that do not respond to conventional treatment, as this combination can benefit the patient.

**Participation of the authors:** *Costa RC*: Literature review,

writing, initial corrections, formatting, and submission to the journal. *Molina JD*: Literature review, writing and updating, submission to the ethics and research committee. *Morgado de Abreu MAM*: Advisor, corrections and final review.

**Conflict of interest:** None to declare

## REFERENCES

1. Barete S. Les mastocytoses. *Ann Dermatol Venerol*. 2014;141:698-714. doi: <https://doi.org/10.1016/j.annder.2014.08.002>.
2. Barros JA, Maluf LC, Machado Filho CD. Mastocitose. *An Bras Dermatol*. 2009;84(3):213-25. doi: <https://doi.org/10.1590/S0365-05962009000300002>.
3. Brockow K. Epidemiology, prognosis, and risk factors in mastocytosis. *Immunol Allergy Clin North Am*. 2014;34(2):283-95. doi: <https://doi.org/10.1016/j.iac.2014.01.003>.
4. Valent P, Akin C, Escribano L, Födinger M, Hartmann K, Brockow K, et al. Standards and standardization in mastocytosis: consensus statements on diagnostics, treatment recommendations and response criteria. *Eur J Clin Invest*. 2007;37:435-53. doi: <https://doi.org/10.1111/j.1365-2362.2007.01807.x>.
5. Czarny J, Lange M, Lugowska-Umer H, Nowicki RJ. Cutaneous mastocytosis treatment: strategies, limitations and perspectives. *Adv Dermatol Allergol*. 2018;35(6):541-5. doi: <https://doi.org/10.5114/ada.2018.77605>.
6. Schneider LA, Hinrichs R, Scharffetter-Kochanek K. Phototherapy and photochemotherapy. *Clin Dermatol*. 2008;26:464-76. doi: <https://doi.org/10.1016/j.clindermatol.2007.11.004>.
7. Brazzelli V, Grassi S, Merante S, Grasso V, Ciccocioppo R, Bossi G, et al. Narrow-band UVB phototherapy and psoralen-ultraviolet A photochemotherapy in the treatment of cutaneous mastocytosis: a study in 20 patients. *Photodermatol Photoimmunol Photomed*. 2016;32:238-46. doi: <https://doi.org/10.1111/phpp.12248>.

Submitted: February 23, 2018

Accepted: June 29, 2020